

CASE REPORT

Open Access



Case report of sigmoid colon perforation and colocutaneous fistula due to retropubic midurethral sling placement for stress urinary incontinence

Xiao Huang*, Hai Jiang and Liping Xie

Abstract

Background: Sigmoid bowel perforation is a very rare and serious complication of the retropubic tension-free vaginal tape (TVT) procedure for female stress urinary incontinence. The complication can be avoided with the use of the correct manipulation technique.

Case presentation: A 75-year-old female patient underwent a retropubic TVT procedure in the local hospital for the treatment of stress urinary incontinence. The procedure was smooth. Two weeks after surgery, the patient began to complain of fever and bloody, purulent discharge from the left suprapubic skin wound. During a 4-month period after surgery, she was admitted to the local hospital 4 times for similar infection symptoms. The infections were temporarily controlled with antibiotic administration. The reason for the refractory infection of the left suprapubic skin wound was not identified until a foreign TVT mesh was found in the sigmoid colon via a colonoscopy. We diagnosed that the TVT mesh caused a sigmoid colon perforation that led to colocutaneous fistula. An exploratory laparotomy revealed that the TVT tape perforated into and out of the sigmoid colon. An 8-cm long left part of mesh was removed. Two ruptures of sigmoid colon were mended without the need for bowel resection. At the 4-years follow-up after laparotomy, the patient was doing well and still continent.

Conclusions: Urologists and gynecologists should be aware of the possibility of colon bowel injury in SUI patients with prior sling surgeries. Patient having recurrent suprapubic cutaneous infection may have high degree of suspicion of colon injury after TVT sling. The passage of the retropubic space procedure should be slow and always along the pubic bone according to the anatomy.

Keywords: Stress urinary incontinence, Tension-free vaginal tape, Sigmoid colon perforation

* Correspondence: xiaohuang69@zju.edu.cn

Department of Urology, The First Affiliated Hospital, School of Medicine, Zhejiang University, No. 79 QingChun Road, Hangzhou 310003, Zhejiang Province, PR China



© The Author(s). 2020 **Open Access** This article is licensed under a Creative Commons Attribution 4.0 International License, which permits use, sharing, adaptation, distribution and reproduction in any medium or format, as long as you give appropriate credit to the original author(s) and the source, provide a link to the Creative Commons licence, and indicate if changes were made. The images or other third party material in this article are included in the article's Creative Commons licence, unless indicated otherwise in a credit line to the material. If material is not included in the article's Creative Commons licence and your intended use is not permitted by statutory regulation or exceeds the permitted use, you will need to obtain permission directly from the copyright holder. To view a copy of this licence, visit <http://creativecommons.org/licenses/by/4.0/>. The Creative Commons Public Domain Dedication waiver (<http://creativecommons.org/publicdomain/zero/1.0/>) applies to the data made available in this article, unless otherwise stated in a credit line to the data.

Background

Stress urinary incontinence (SUI) is a major urological/gynecological problem. As many as 25% of women older than 20 years have urinary incontinence [1]. The retropubic tension-free vaginal tape (TVT) procedure has become the standard of care for SUI with demonstrated efficacy and limited complications since its introduction in 1996 by Ulmsten et al. [2]. However, complications do occur during or after the procedure, ranging from bladder perforation (3.8%), urethral lesion (0.07%) to intestinal injury (0.03–0.7%) [3, 4]. Bowel injuries have rarely been reported in the literature, with most reported cases involving the small intestine becoming clinically apparent in perioperative period after the procedure [5, 6]. In some cases, bowel perforations may be found very late ranging from several months to years [7–9], especially in cecum [10] and sigmoid colon [11], which is very similar to what was found in our case but that occurred 7 years after surgery. We recently experienced a case of sigmoid colon perforation and colocutaneous fistula 2 weeks after the TVT tape procedure was performed.

Case presentation

A 75-year-old woman was referred to our center from local hospital with a history of a retropubic TVT sling (TVT-Exact; Gynecare) procedure performed 4 months ago due to SUI. The procedure was smooth. The patient began to complain of fever (with body temperature from 37.8–38.6 °C) and bloody, purulent discharge from left suprapubic skin wound 2 weeks after the TVT surgery. No nausea and vomiting. No peritoneal irritation sign. The volume of purulent discharge from skin fistula was 5–10 ml per day. Laboratory data showed elevated levels of white blood cells of $1.2 \times 10^9/L$ and C-reactive protein (CRP) of 20.85 mg/L. The patient had been admitted to the local hospital 4 times because of similar symptoms in those 4 months after surgery. After the administration of kanamycin or quinolones antibiotics for about 3–7 days, the patient's symptoms were resolved completely between episodes. The left suprapubic infection and the tape exit wound purulent discharge was recurrent and could be temporarily controlled after antibiotic administration. Cystoscopy showed no bladder injury. The reason for recurrent left suprapubic wound infection was finally identified by a colonoscopy in local hospital, which showed a foreign TVT tape mesh in the sigmoid colon cavity approximately 30 cm from the anal orifice (Fig. 1). The patient was then transferred to our center for further treatment. The patient denied urinary symptoms and was continent. She had no abdominal surgery history before this TVT procedure. Her medical history was significant for diabetes mellitus II, and the blood glucose levels were well controlled with insulin and acarbose. Upon physical examination, the patient's vital signs

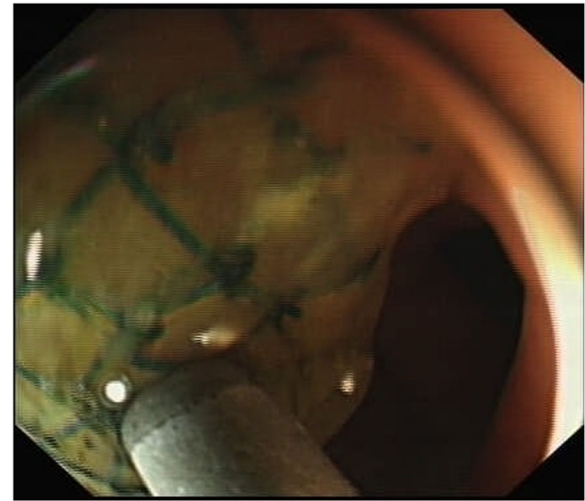


Fig. 1 A foreign mesh was revealed in the sigmoid colon 30 cm from the anal orifice via colonoscopy

were normal. The abdomen was flat with no signs of peritonitis. There was a 1 × 1-cm red swollen area at the left suprapubic skin with purulent secretion. Abdominal computed tomography (CT) showed a thickened left bladder wall and internal iliac muscle. No abscess was found in the pelvic cavity (Fig. 2). We diagnosed that the TVT mesh caused a sigmoid colon perforation that led to colocutaneous fistula. An exploratory laparotomy was performed through an incision in the midline of the lower abdomen. The TVT tape was found to have perforated the sigmoid bowel in an in-and-out fashion before exiting at the suprapubic skin incision. The sigmoid colon was fixed to the abdominal wall by the tape. After the two sides of the tape were mobilized and cut, an 8 cm-long whole left part of the mesh was entirely removed from the sigmoid colon and the retropubic space

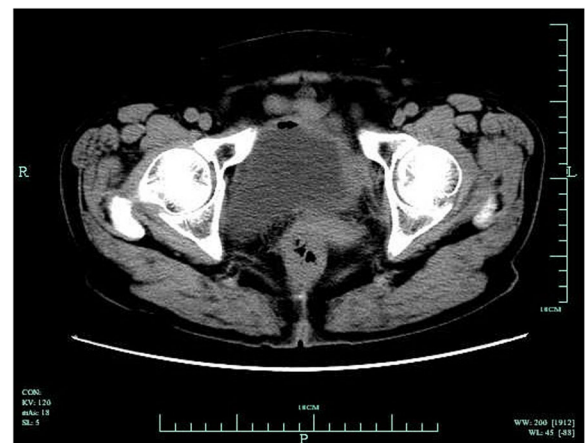

Fig. 2 Computed tomography showing the thickened local left bladder wall and the internal iliac muscle

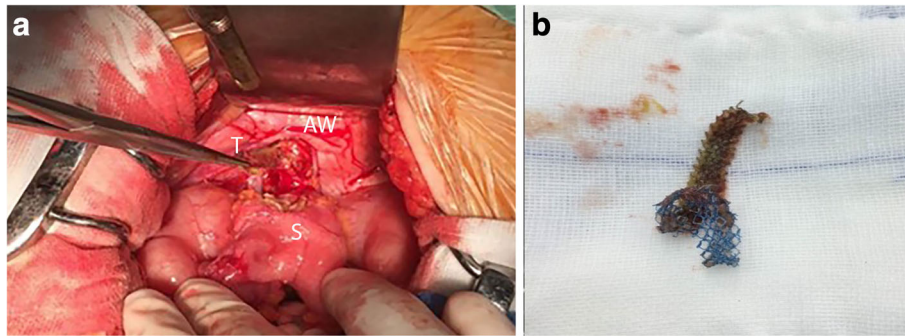


Fig. 3 A The sigmoid colon was perforated and fixed to the left abdominal wall (AW, abdominal wall; T, tape; S, sigmoid) by an 8-cm long TVT tape. b The foreign tape was removed with exploratory laparotomy. The brown part of the tape was in the sigmoid cavity, and the blue part was out of the sigmoid cavity

(Fig. 3). The two ruptures of the sigmoid colon were mended with intermittent sutures. No resection of the bowel was needed. The patient recovered well from the procedure and was discharge 2 weeks after the surgery. Four years following the laparotomy and partial tape removal, the patient was doing well and still continent.

Discussion and conclusions

Although the retropubic TVT sling procedure has been demonstrated to be a safe and effective surgery for SUI, there have been reports of complications, such as hematoma formation, urinary retention and mesh erosion [3, 4]. Bowel perforation which is reported in only 0.03%~0.7% of sling surgeries, is a very rare complication of TVT type sling procedures [4]. Most cases have been reported in patients with a previous history of abdominal or pelvic surgery [7–9]. However, our patient had no history of abdominal or pelvic surgery. When bowel injury is noted, it typically involves displacement of the mesh into the abdominal cavity with resulting perforation of the bowel.

Bowel injuries involving the small intestine usually have acute symptoms such as fever, nausea, vomiting, abdominal pain, distention and diminished bowel sounds because of peritonitis and bowel obstruction and can be diagnosed early [5, 6]. Whereas bowel injuries involving colon [10, 11], it may be found very late ranging from several months to years. Our patient had none of the general symptoms described above. But she mainly had a local suprapubic skin infection, similar to the case reported in the literature [11], which occurred 7 years after surgery. In our case, the sigmoid colon perforation occurred during the surgery. But it took 4 months for surgeons in the local hospital to identify the bowel injury. Therefore, a colonoscopy examination may be needed immediately if a recurrent local infection cannot be explained after the TVT procedure. In our case, it appeared that the intraperitoneal placement of the TVT

tape had just perforated into the sigmoid colon and fixed the colon segment to the abdominal wall. The subsequent infection occurred between the involved sigmoid colon and subcutaneous tissue along the tape, so the patient had no symptoms of peritonitis or bowel obstruction but only a local skin fistula formation.

The reason for this complication may be the surgeon's lack of experience. According to the standard TVT technique, the skin site of the tape exit should be 2 cm from the midline, and the passage of the retropubic space procedure should be slow and always along the pubic bone according to the anatomy. The force and direction of the puncture should be well controlled, so that the passage of the needle is not too fast accidentally entering the abdominal cavity. Because of the blind passage technique, bowel perforations may not be immediately recognized during the surgery. The blind passage technique limits the utility of observation, so a close observation of trainees is strongly recommended. Before performing the TVT procedure alone, all trainees should have sufficient practice under the observation of an experienced surgeon. Clinical suspicion of bowel injury must be maintained for any unexplained postoperative abdominal symptoms. Patient having recurrent suprapubic subcutaneous infection may have high degree of suspicion of colon injury after TVT sling. Colonoscopy is needed to verify the suspicion. After bowel injury is confirmed, an open or laparoscopic exploratory laparotomy [11] with excision of the mesh and repair of the bowel should be performed promptly.

Abbreviations

SUI: Stress urinary incontinence; TVT: Tension-free vaginal tape; CT: Computed tomography; CRP: C-reactive protein

Acknowledgements

Not applicable.

Statement

I adhered to CARE guidelines/methodology.

Authors' contributions

XH: First assistant of the laparotomy procedure, Data collection and analysis, manuscript writing. HJ: Treatments design, chief surgeon of the laparotomy procedure, acquisition of data, manuscript drafting; LX: Treatments design and supervision, participant of the laparotomy procedure, manuscript drafting and important revision. All authors have read and approved the final manuscript.

Funding

The funder of Natural Science Foundation of Zhejiang Province (number: LY19H050008) which was granted to Dr. Xiao Huang will cover the publication fee.

Availability of data and materials

The datasets used and analysed during the current study are available from the corresponding author on reasonable request.

Ethics approval and consent to participate

The manuscript entitled "Case report of sigmoid colon perforation and colocutaneous fistula due to retropubic midurethral sling placement for stress urinary incontinence" is under the permission and consent to participate from The ethics committee of the Zhejiang University First affiliated Hospital.

Consent for publication

I declare that the written consent was obtained from the participant. We received the consent to publish from the patient herself. We keep the "Consent form" for request anytime.

Competing interests

The authors declare that they have no competing interests.

Received: 8 December 2019 Accepted: 9 March 2020

Published online: 20 March 2020

References

- Holroyd-Leduc JM, Straus SE. Management of urinary incontinence in women: scientific. Review. *JAMA*. 2004;291:986–95.
- Schierlitz L, Dwyer P, Rosamilia A, et al. Effectiveness of tension-free vaginal tape compared with transobturator tape in women with stress urinary incontinence and intrinsic sphincter deficiency. *Obstet Gynecol*. 2008;112:1253–61.
- Kuuva N, Nilsson CG. A nationwide analysis of complications associated with the tension-free vaginal tape (TVT) procedure. *Acta Obstet Gynecol Scand*. 2002;81(1):72–7.
- Gomes CM, Carvalho FL, Bellucci CHS, et al. Update on complications of synthetic suburethral slings. *Int Braz J Urol*. 2017;43(5):822–34.
- Gurshumov EL, Klapper AS, Sierecki AR. Small bowel perforation in a hernia sac after TVT placement at the time of colpocleisis. *Int Urogynecol J*. 2010;21(3):371–3.
- Huffaker RK, Yandell PM, Shull BL. Tension-free vaginal tape bowel perforation. *Int Urogynecol J*. 2010;21(2):251–3.
- Phillips L, Flood CG, Schulz JA. Case report of tension-free vaginal tape-associated bowel obstruction and relationship to body habitus. *Int Urogynecol J Pelvic Floor Dysfunct*. 2009;20(3):367–8.
- Westermann LB, Brown A, Long JB. Delayed presentation of an enterocutaneous fistula after tension-free vaginal tape sling. *Female Pelvic Med Reconstr Surg*. 2011;17(5):258–9.
- Elliott JE, Maslow KD. Remote discovery of an asymptomatic bowel perforation by a mid-urethral sling. *Int Urogynecol J*. 2012;23(2):243–5.
- Lee IK, Sohn DW. Delayed sigmoid colon perforation and enterocutaneous fistula due to tension free transvaginal tape operation for stress urinary incontinence. *Can Urol Assoc J*. 2015 Mar-Apr;9(3–4):E208–9.
- Mayhew AC, Ford AT, Northington GM, et al. Delayed presentation of Cecal perforation with tension-free vaginal tape. *Obstet Gynecol*. 2018;131(3):499–502.

Publisher's Note

Springer Nature remains neutral with regard to jurisdictional claims in published maps and institutional affiliations.

Ready to submit your research? Choose BMC and benefit from:

- fast, convenient online submission
- thorough peer review by experienced researchers in your field
- rapid publication on acceptance
- support for research data, including large and complex data types
- gold Open Access which fosters wider collaboration and increased citations
- maximum visibility for your research: over 100M website views per year

At BMC, research is always in progress.

Learn more biomedcentral.com/submissions

