

CASE REPORT

Open Access



Endoscopic combined intrarenal surgery in the prone-split leg position for successful single session removal of an encrusted ureteral stent: a case report

Daming Wang[†], Hongliang Sun[†], Lei Chen, Zhiqi Liu, Dazhao Zhang, Dexin Yu and Demao Ding^{*}

Abstract

Background: The most serious complication of ureter stent is long-term retention of ureteral stent and stone formation around the stent.

Case presentation: A 51-year old female patient with left ureteral stent placed 2 years before developed both pyelic and vesical stones on the two ends of the double J was admitted to our hospital. Intravesical lithotripsy, retrograde ureteroscopy, and percutaneous nephrolithotripsy were performed with the patient in the prone split-leg position. All the stones and the ureteral stent were successfully removed in a single session.

Conclusions: Combined endoscopic techniques in the prone split-leg position can effectively and safely manage severely encrusted stents.

Keywords: Prone-split leg position, Encrusted ureteral stent, Endoscopic combined intrarenal surgery

Background

Ureteral stent was introduced in 1974 to relieve ureteral obstruction and play an important role in the advance of endourology [1]. Nowadays, ureteral stent was widely used in ureteral calculi, stricture operation, ureteral injury and relieving tumor compression. However, the potential complications of ureteral stent placement include hematuria, infection, pain, ureteral injury, displacement, stone formation and encrustation. The ureteral stent should be implanted by fully trained personnel to avoid improper ureteral stent operation. It is suggested that cystoscopy and / or X-ray should be used to check the ureteral stent for signs of encrusted and normal function. Ureteral stent is not a permanent retention device and should not be placed in the body beyond the specified

time. The delayed removal of ureteral stent increases the incidence of encrusted ureteral stent with prolonged retention time. Bostanci et al. reported that the incidence of the patients who forgot to take out the stent with encrustation was about 0.64% [2]. The initial recommendations for the management of an encrusted stent include shock wave lithotripsy, ureteroscopy lithotripsy (URSL) and percutaneous nephrolithotripsy (PCNL). However, if the stone around the stent tube is too large to be completely removed, it may need to be treated by extracorporeal lithotripsy or surgery many times, which can cause great pain and financial burden to the patients. This report presents an interesting case of successful removal of an encrusted ureteral stent in a single session by endoscopic combined intrarenal surgery (ECIRS).

Case presentation

A 51-year-old female patient underwent left URSL 2 years ago. However, she lose follow-up before complete

* Correspondence: ddmstone@163.com

[†]Daming Wang and Hongliang Sun contributed equally to this work. Department of Urology, The Second Affiliated Hospital of Anhui Medical University, Hefei 230601, China



© The Author(s). 2020 **Open Access** This article is licensed under a Creative Commons Attribution 4.0 International License, which permits use, sharing, adaptation, distribution and reproduction in any medium or format, as long as you give appropriate credit to the original author(s) and the source, provide a link to the Creative Commons licence, and indicate if changes were made. The images or other third party material in this article are included in the article's Creative Commons licence, unless indicated otherwise in a credit line to the material. If material is not included in the article's Creative Commons licence and your intended use is not permitted by statutory regulation or exceeds the permitted use, you will need to obtain permission directly from the copyright holder. To view a copy of this licence, visit <http://creativecommons.org/licenses/by/4.0/>. The Creative Commons Public Domain Dedication waiver (<http://creativecommons.org/publicdomain/zero/1.0/>) applies to the data made available in this article, unless otherwise stated in a credit line to the data.

removal ureteral stent. Recently, she presented to the department of urology with left lumbar pain. She suffered from urgency and frequency of urination and without the history of other diseases and operation. Physical examination: Body mass index was 25.12 kg/m², left renal percussive pain was positive. An abdominal radiograph showed that both end of ureter stent encrusted with the stone (Fig. 1). Computed tomography (CT) examination reported that a single large stone, located in the renal pelvis and bladder, wrapped around the end of the stent tube, with a length of more than 2 cm (Fig. 2). The CT Hounsfield Unit value of left intrarenal calculi was 645HU, and that of bladder calculi was 1150HU. Urinalysis testing revealed a red blood cell count of > 100/hp. and a white blood cell count of 120/hp. Urine bacterial culture suggested the presence of *Escherichia coli*. Other routine laboratory examinations were all within normal limits.

According to the results of urinary bacterial culture, the third generation cephalosporins was selected for anti-infection treatment for 5 days. Stent removal was attempted by ECIRS under general anesthesia. The patient was oriented in the prone-split leg position throughout the operation, and then we performed retrograde operation and PCNL (Fig. 3). The operation was performed by two urologists at the same time, one performed PCNL, the other performed transurethral retrograde surgery. First, Surgeon 2 was performed nephroscope (f20, Wolf, Germany) combined with resectoscopes sheath (f26.5) to enter bladder, observed the stent encrustation and located the ureteral orifice. The

distal end of the ureteral stent was highly encrusted, the diameter was about 2 cm. Pneumatic ballistic gravel (Electro Medical Systems, Swiss LithoClast® Maste, Nyon, Switzerland) entered into the bladder through nephrosopes (Fig. 4), and the stone fragment was rushed out. The Surgeon 2 retrograde entered into the left ureteral orifice with a ureterscope (Karl Storz, Tuttlingen, Germany), and then entered the left renal pelvis along the stent tube and guide wire. The ureter was in good condition without stricture and damage, and there were no encrusted in the middle of stent tube. Under ultrasound guidance, surgeon 1 chose the left posterior axillary line under 12 ribs as the puncture position and established the nephroscope channel (f22). Meanwhile, surgeon 2 monitored the dilation and establishment of puncture channel with ureterscope to avoid kidney injury caused by too deep puncture channel (Fig. 5). Surgeon 1 entered the renal pelvis with a nephroscope (f20, Wolf, Germany). Ultrasonic lithotripter (ultrasonic energy 80%, duty cycle 70%, Electro Medical Systems, Swiss LithoClast® Maste, Nyon, Switzerland) removed the stent encrustation in the renal pelvis, broke the stones into smaller fragments. The fragments were drawn from the channel with negative pressure (Additional file 1). After removal of intrarenal calculi, the stent tube was removed completely by foreign body forceps through the channel. No residual stone was found in the renal pelvis and ureter (Fig. 6). Finally, a new stent tube (f6, 28 cm, urovision) was placed into the ureter, and ECIRS was used to ensure the correct position of the stent tube. The total operation time was 74 min. There was no complication after the operation. No residual stone was found in postoperative reexamination imaging. The nephrostomy tube was removed five days after surgery. The ureteral stent was removed one month later. An analysis of the encrusting material indicated that it was a calcium phosphate calculus.

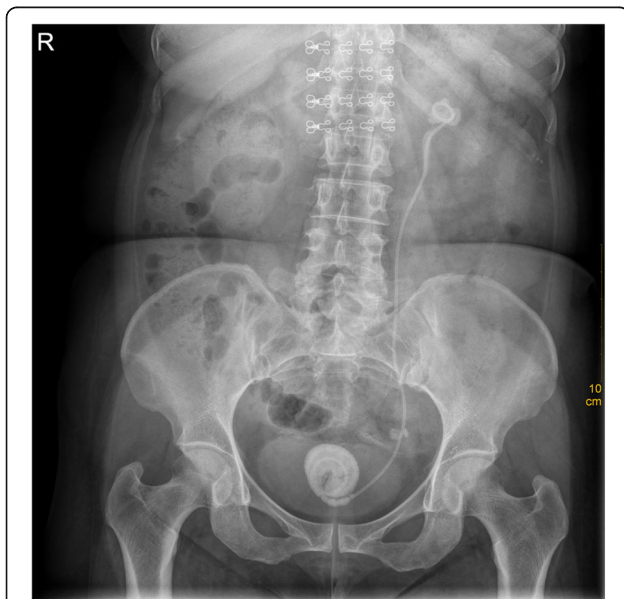

Fig. 1 The abdominal radiograph showed that circular encrustations completely encasing both of the pigtail portions of the indwelling ureteral stent

Discussion and conclusion

With the improvement of medical technology and the application of new biomaterials and ureteral stent coatings, the incidence of infection and encrustation has declined significantly [3]. However, many studies indicated that ureter stent indwelling time is highly associated with the incidence of encrustation [4]. El-Faqih et al. reported that the stent encrustation rate increases from 9.2% for an indwelling time of less than 6 weeks to 76.3% for more than 12 weeks [5]. Severe encrustation with stone formation can lead to urinary tract obstruction, infection, and kidney damage. Hence, stent encrustation must choose a reasonable surgical method to avoid ureteral injury, stent rupture and multiple operations. The case we reported may provide an effective surgical approach to remove an encrusted ureteral stent.

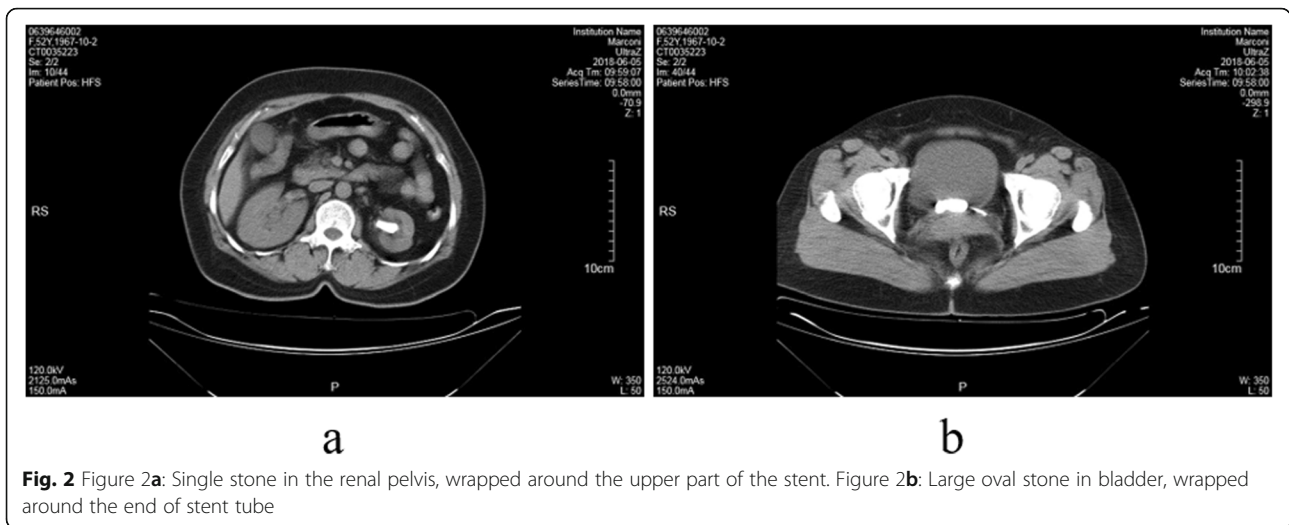


Fig. 2 Figure 2a: Single stone in the renal pelvis, wrapped around the upper part of the stent. Figure 2b: Large oval stone in bladder, wrapped around the end of stent tube

Acosta-Miranda et al. reported that according to the imaging examination, the stent encrustation is graded to facilitate the selection of treatment methods [6]. This classification is based on the stone size, location, and degree of stent encrustation. According to the above grading method, the cases reported in this study are grade IV. The diameter of circular encrustations at both ends is greater than 2 cm. Many studies have pointed out that different methods of lithotripsy should be used at the upper and lower ends of this case [6, 7]. However, how

to remove the stent tube and stone by a combination of different lithotripsy methods in one position.

If the patient want to perform operation, the first step is to perform cystoscopic lithotripsy and URSL in the lithotomy position, and then to perform PCNL in the prone position. It may cause prolonged operation time, repeated placement of body position during operation, fracture of stent tube and residual stone. In the prone-split leg position, ECIRS has obvious advantages in the treatment of severe stent encrustation. Avoiding the

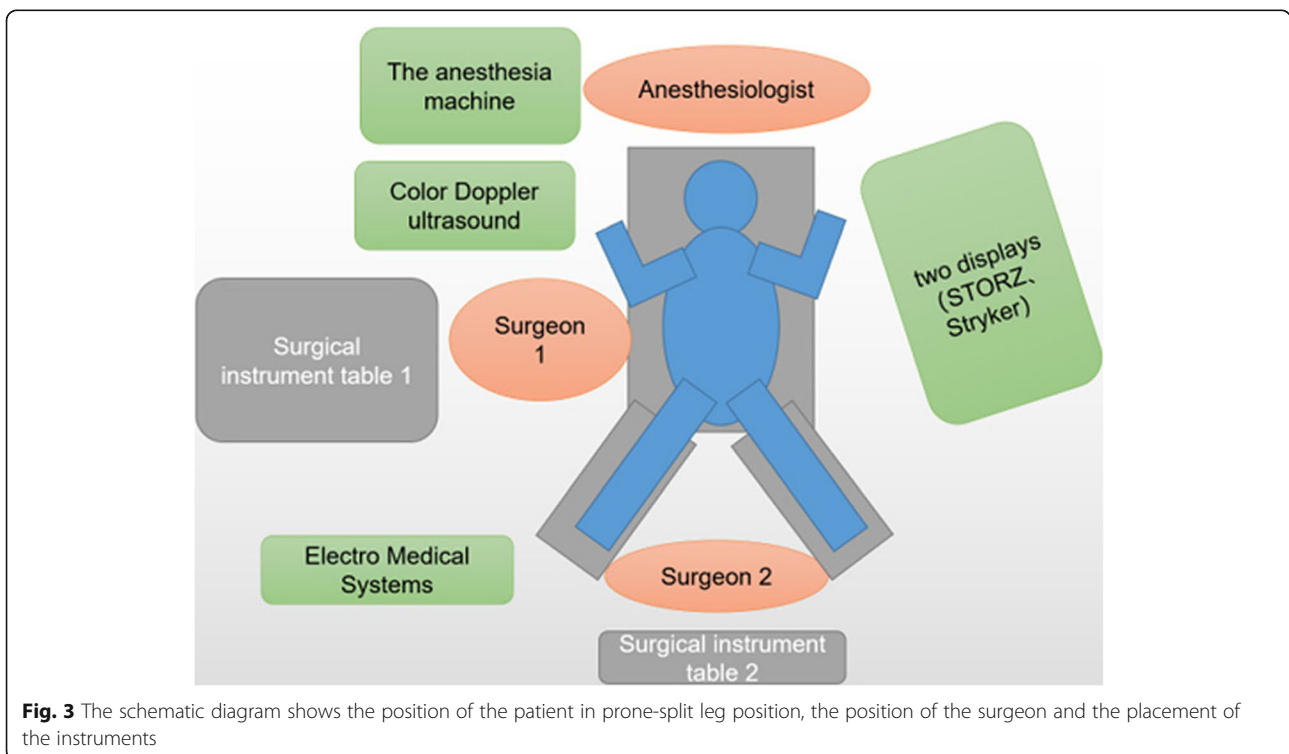


Fig. 3 The schematic diagram shows the position of the patient in prone-split leg position, the position of the surgeon and the placement of the instruments

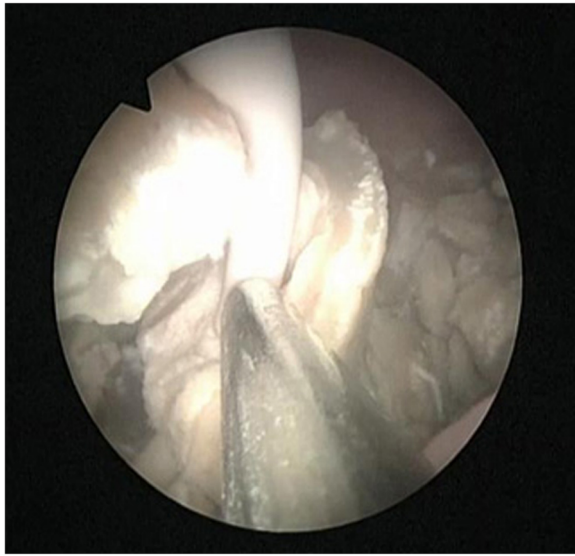


Fig. 4 The distal end of the ureteral stent was severe encrusted, the diameter is about 2 cm. Pneumatic ballistic gravel through nephrosopes into the bladder

repeated placement of body position during an operation to ensure the continuity of operation. The combination of two kinds of endoscopes in the same operation has good complementarity. For renal pelvis stone, the combination of upper and lower endoscopy increases the operation field of vision and expands the operation angle. As a result, the ECIRS increases the extent of the rubble. Besides, in the prone position, the ureteral channel tends to be straight under the action of gravity, making it

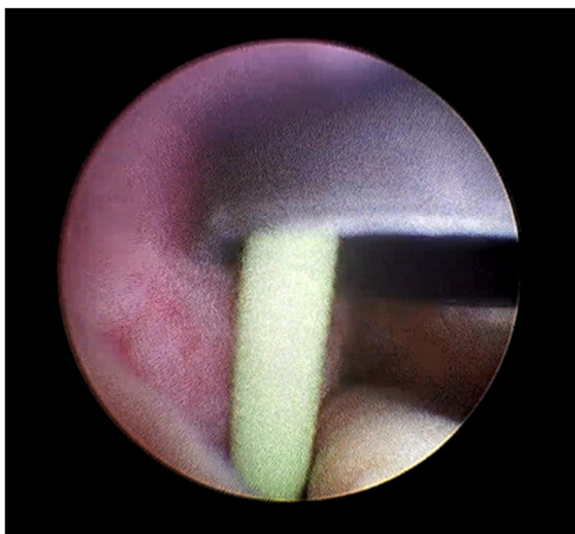


Fig. 5 The ureteroscope enters the left renal pelvis along the stent tube and guide wire, ureteroscope to monitor the dilation and establishment of puncture channel in renal pelvis



Fig. 6 Ureteral stent and stone were removed completely

easier for ureteroscopy to enter the upper ureter and renal pelvis [8]. Under monitor of the ureteroscopy, the dilation of the percutaneous nephroscope puncture channel can avoid renal injury [9]. The mutual drainage channel can reduce the pressure in the renal pelvis and reduce the extravasation of the perfusion during the high-pressure washing of the lithotripsy. Thereby reducing the risk of postoperative infection. Different from other reports [10–12], this case is treated in one position combined with intravesical lithotripsy, retrograde ureteroscopy and percutaneous nephrolithotripsy. The whole process of puncture and removal of stent tube is monitored. In addition, the operation is successful once, avoiding reoperation, repeatedly placing the body position, stent rupture and open bladder operation. Tetsuya Isero et al. reported that a case of severe stent encrustation is successfully removed by flexible ureteroscopy and miniature nephroscopy in the prone split-leg position [13]. Compared with the Galdakao-modified supine Valdivia position [10, 14], the prone split-leg position has the following advantages: (1) The operator is familiar with the position and easy to place. The percutaneous nephroscopy puncture space is larger and the risk of visceral injury is smaller. (2) There are no obesity and cardiopulmonary disease in the patients. But the prone position had no significant effect on their cardiopulmonary function. (3) Avoiding long-term elevation of lower

limbs and compression of blood vessels. Most of the stent encrustation are phosphate (struvite) and calcium phosphate crystals [15]. The analysis of this case is calcium phosphate calculus. Continue to use sensitive antibiotics and reduce urine pH value after operation. For patients with stent placement, strict follow-up can effectively prevent stent from being forgotten and stone formation.

In summary, a case of severe ureteral stent encrustation is successfully treated by endoscopy combined in one position. The stone and stent are removed completely in one operation, avoiding the change of body position and reoperation. The removal of stent is completely monitored to avoid rupture of stent and ureteral injury. The combination of upper and lower endoscopy can enlarge the operative field of vision and reduce the injury. Thus, ECIRS in the prone-split leg position could achieve successful and safe management of severe encrusted stents.

Abbreviations

URSL: Ureteroscopy lithotripsy; PCNL: Percutaneous nephrolithotripsy; FURSL: Flexible ureteroscopy lithotripsy; ECIRS: Endoscopic combined intrarenal surgery; CT: Computed tomography

Acknowledgements

No applicable.

Authors' contributions

Manuscript writing: WDM. Data collection and management: WDM, SHL, CL. Manuscript editing: SHL, LZQ, ZDZ, YDX, DDM. Protocol: YDX, DDM. Project development: YDX, DDM. Data analysis: DDM. The authors read and approved the final manuscript.

Funding

No funding was obtained for this study.

Availability of data and materials

The datasets used during this study available from the corresponding author on reasonable request.

Ethics approval and consent to participate

No applicable.

Consent for publication

Written informed consent was obtained from the patient for publication of this case report and any accompanying images. A copy of the written consent is available for review by the Editor of this journal.

Competing interests

The authors declare that they have no conflict of interests.

Received: 24 December 2019 Accepted: 25 March 2020

Published online: 06 April 2020

References

- Gibbons RP, Mason JT, Correa RJ. Experience with indwelling silicone rubber ureteral catheters. *J Urol*. 1974;111(5):594–9.
- Bostanci Y, Ozden E, Atac F, Yakupoglu YK, Yilmaz AF, Sarikaya S. Single session removal of forgotten encrusted ureteral stents: combined endourological approach. *Urol Res*. 2012;40(5):523–9.
- Mosayyebi A, Manes C, Carugo D, Somani BK. Advances in ureteral stent design and materials. *Curr Urol Rep*. 2018;19(5):35.
- Kawahara T, Ito H, Terao H, Yoshida M, Matsuzaki J. Ureteral stent encrustation, incrustation, and coloring: morbidity related to indwelling times. *J Endourol*. 2012;26(2):178–82.

- El-Faqih SR, Shamsuddin AB, Chakrabarti A, Atassi R, Kardar AH, Osman MK, Husain I. Polyurethane internal ureteral stents in treatment of stone patients: morbidity related to indwelling times. *J Urol*. 1991;146(6):1487–91.
- Acosta-Miranda AM, Milner J, Turk TM. The FECal double-J: a simplified approach in the management of encrusted and retained ureteral stents. *J Endourol*. 2009;23(3):409–15.
- Weedin JW, Coburn M, Link RE. The impact of proximal stone burden on the management of encrusted and retained ureteral stents. *J Urol*. 2011;185(2):542–7.
- Hamamoto S, Yasui T, Okada A, Takeuchi M, Taguchi K, Shibamoto Y, Iwase Y, Kawai N, Tozawa K, Kohri K. Developments in the technique of endoscopic combined intrarenal surgery in the prone split-leg position. *Urology*. 2014;84(3):565–70.
- Kaler KS, Parkhomenko E, Lin CY, Valley ZA, Kim WK, Okhunov Z, Patel RM, Landman J. A new twist on an old technique: Lawson retrograde endoscopic-guided nephrostomy access for percutaneous Nephrolithotomy in prone Split-leg position. *J Endourol Case Rep*. 2018;4(1):190–4.
- Usui K, Asai T, Tabei T, Ito H, Komeya M, Fujikawa A, Matsuzaki J. A case of endoscopic combined Intrarenal surgery for multiple encrusted stones on a forgotten ureteral stent left for 4 years. *Hinyokika kiyo. Acta Urologica Japonica*. 2016;62(11):585–9.
- Torricelli FCM, Berjeaut RH, Laffeira L, Yamauchi FI, Marchini GS, Nahas WC, Srougi M, Mazzucchi E. Complete calcified ureteral stent: a combined 1-session approach. *Urology*. 2017;110:259–61.
- Farshid S, Sharifi-Aghdas F, Varyani M. Fragmented ureteral stent extraction by antegrade and retrograde access: using ureteroscopy and nephroscope. *Urol Case Rep*. 2019;24:100871.
- Isero T, Hamamoto S, Koiba S, Kamiya H, Hashimoto Y, Yasui T, Iwase Y, Kohri K. Combined endoscopic surgery in the prone-split leg position for successful single-session removal of an encrusted ureteral stent: a case report. *J Med Case Rep*. 2014;8:128.
- Scoffone CM, Cracco CM, Cossu M, Grande S, Poggio M, Scarpa RM. Endoscopic combined intrarenal surgery in Galdakao-modified supine Valdivia position: a new standard for percutaneous nephrolithotomy? *Eur Urol*. 2008;54(6):1393–403.
- Ulker V, Celik O. Endoscopic, Single-Session Management of Encrusted, Forgotten Ureteral Stents. *Medicina (Kaunas, Lithuania)*. 2019;55(3):58.

Publisher's Note

Springer Nature remains neutral with regard to jurisdictional claims in published maps and institutional affiliations.

Ready to submit your research? Choose BMC and benefit from:

- fast, convenient online submission
- thorough peer review by experienced researchers in your field
- rapid publication on acceptance
- support for research data, including large and complex data types
- gold Open Access which fosters wider collaboration and increased citations
- maximum visibility for your research: over 100M website views per year

At BMC, research is always in progress.

Learn more biomedcentral.com/submissions

