

CASE REPORT

Open Access

Spontaneous bilateral renal pelvis rupture during CT in the absence of urinary tract obstruction: case report



Zongchen Li^{1*}  and Joey Chan Yiing Beh²

Abstract

Background: Atraumatic renal pelvis rupture without pre-existing renal or ureteric pathology is an uncommon event. It is reported in the setting of acute urinary tract obstruction, most often secondary to ureteric calculi. Typical symptoms include acute flank pain and nausea, mimicking pyelonephritis or other causes of acute abdomen. Spontaneous rupture occurring bilaterally without identifiable urinary tract obstruction is exceedingly rare, and has yet to be reported in current English literature. Possible contributing pathophysiological mechanisms can be postulated from reported cases of rupture with observed obstruction.

Case presentation: A 58-year-old woman undergoing multiphasic computed tomography (CT) for evaluation of asymptomatic microscopic haematuria developed on-table bilateral renal pelvis rupture seen only after contrast administration, on the delayed phase. There was no significant past medical history of note. The patient remained asymptomatic throughout and after the study, and was managed conservatively. Follow-up radiographical imaging over a month showed resolution of urinoma and no further contrast extravasation. No complications or recurrence was subsequently noted.

Conclusions: Spontaneous rupture of the renal pelvis can be a rare complication of intravenous contrast administration even in cases without identifiable urinary tract obstruction, and it can occur bilaterally. Cases can uncommonly be asymptomatic but typical symptoms should prompt evaluation of the kidneys, particularly when they are not included in the initial study or no delayed phase is protocolled. Interval imaging for resolution of urinoma and contrast extravasation is clinically relevant to monitor for and avoid infective sequelae.

Keywords: Spontaneous renal pelvis rupture, Forniceal rupture, Pyelosinus backflow, Contrast-induced osmotic diuresis, Case report

* Correspondence: lizongchen27@hotmail.com

¹National University Hospital, Singapore, Singapore

Full list of author information is available at the end of the article



© The Author(s). 2020 **Open Access** This article is licensed under a Creative Commons Attribution 4.0 International License, which permits use, sharing, adaptation, distribution and reproduction in any medium or format, as long as you give appropriate credit to the original author(s) and the source, provide a link to the Creative Commons licence, and indicate if changes were made. The images or other third party material in this article are included in the article's Creative Commons licence, unless indicated otherwise in a credit line to the material. If material is not included in the article's Creative Commons licence and your intended use is not permitted by statutory regulation or exceeds the permitted use, you will need to obtain permission directly from the copyright holder. To view a copy of this licence, visit <http://creativecommons.org/licenses/by/4.0/>. The Creative Commons Public Domain Dedication waiver (<http://creativecommons.org/publicdomain/zero/1.0/>) applies to the data made available in this article, unless otherwise stated in a credit line to the data.

Background

Spontaneous renal pelvis rupture, also known as fornical rupture or pyelosinus backflow, is an uncommon complication of acute urinary tract obstruction. In the context of intravenous urography during acute renal colic, Schwartz et al. defined a rupture as 'spontaneous' if it occurred in the absence of trauma, abdominal compression, destructive renal lesion or prior surgical and endoscopic intervention [1].

It is thought to occur as a result of rapidly increasing intraluminal pressure [2] presumably overwhelming slower reactive mechanisms that act to reduce urine output, as seen in chronic hydronephrosis. Typical symptoms mimic those of acute abdomen or pyelonephritis, with unilateral flank pain and nausea [3]. This event has been reported most frequently in association with obstructive ureteric calculi, with other aetiologies such as extrinsic ureteric compression or bladder outlet obstruction following distantly behind [4].

Asymptomatic spontaneous rupture occurring bilaterally in the absence of urinary tract obstruction is hence extremely unusual. To the best of the authors' knowledge, this has not been described in current English literature. We report one such case precipitated by CT

urography and discuss possible pathophysiological mechanisms.

Case presentation

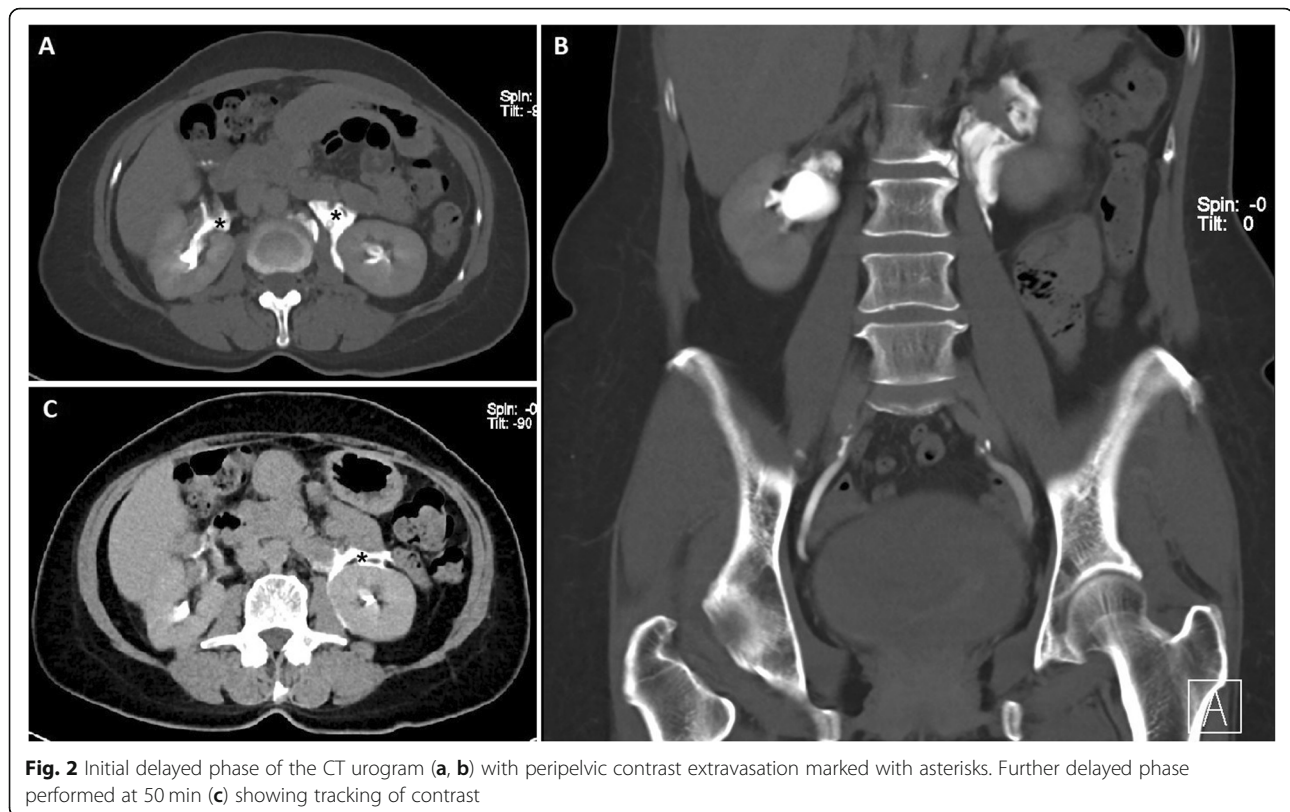
A 58-year-old woman with no significant past medical history was referred to the outpatient urology clinic for asymptomatic microscopic haematuria noted incidentally on urinalysis. Routine CT urography was performed in the pre-contrast, nephrographic and delayed phases. A total of 75 mL of iodinated contrast agent (300 mg I/mL concentration) was administered, and no diuretics were given.

On the pre-contrast and nephrographic phases, a 2 mm non-obstructive renal calculus was noted on the right but the kidneys were otherwise unremarkable. No calculus was seen in the ureters and urinary bladder (Fig. 1). The latter was well-distended from voluntary retention of urine in preparation for the study. No perinephric fluid collection was noted at this point.

On the excretory phase performed at 6 min 13 s post-contrast, peripelvic contrast extravasation was observed bilaterally - suggestive of acute rupture (Fig. 2). No other site of urinoma was observed. A further delayed phase was performed at 50 min post-contrast to evaluate the

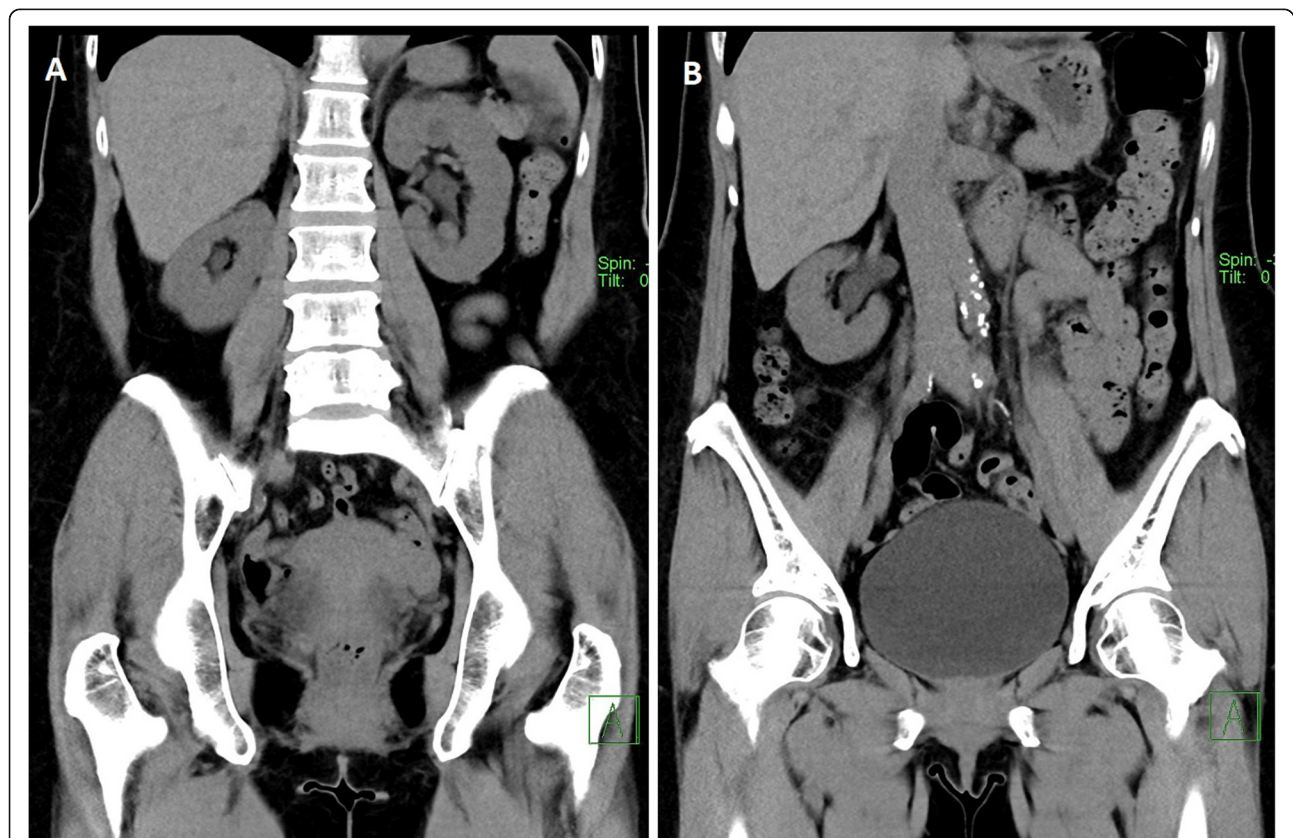

Fig. 1 Non-contrast phase of the CT urogram showing no hydronephrosis or hydroureter bilaterally (a), and a well-distended urinary bladder (b). No ureteric or bladder calculus was seen



extent of urinoma, which showed tracking of contrast along the retroperitoneum without further peripelvic extravasation.

Throughout the study, no flank pain or other symptom was reported; the patient remained asymptomatic even after the event was observed acutely on-table. No abdominal or flank tenderness was elicited on examination.

She was managed conservatively and a radiograph performed the next day revealed no persistent contrast pooling. Follow-up intravenous urography performed a month after showed no recurrence of contrast extravasation (Fig. 3). Thereafter, she was discharged from follow-up after resolution of microscopic haematuria.

Discussions and conclusions

This is a case demonstrating an exceedingly rare radiological event in the absence of classically associated risk factors. Reviewing related case reports, we discuss possible pathophysiological mechanisms though these are difficult to prove with a single case alone.

Rupture is reported to occur when intra-pelvic pressures exceed 25 to 75 mmHg and is seen most frequently at the fornices [5], possibly where the walls are the thinnest. Iodinated contrast agents are potent osmotic diuretics, and their role in precipitating rupture during an acute obstruction is clear. An early prospective study by Bernardino et al. demonstrated a positive relationship

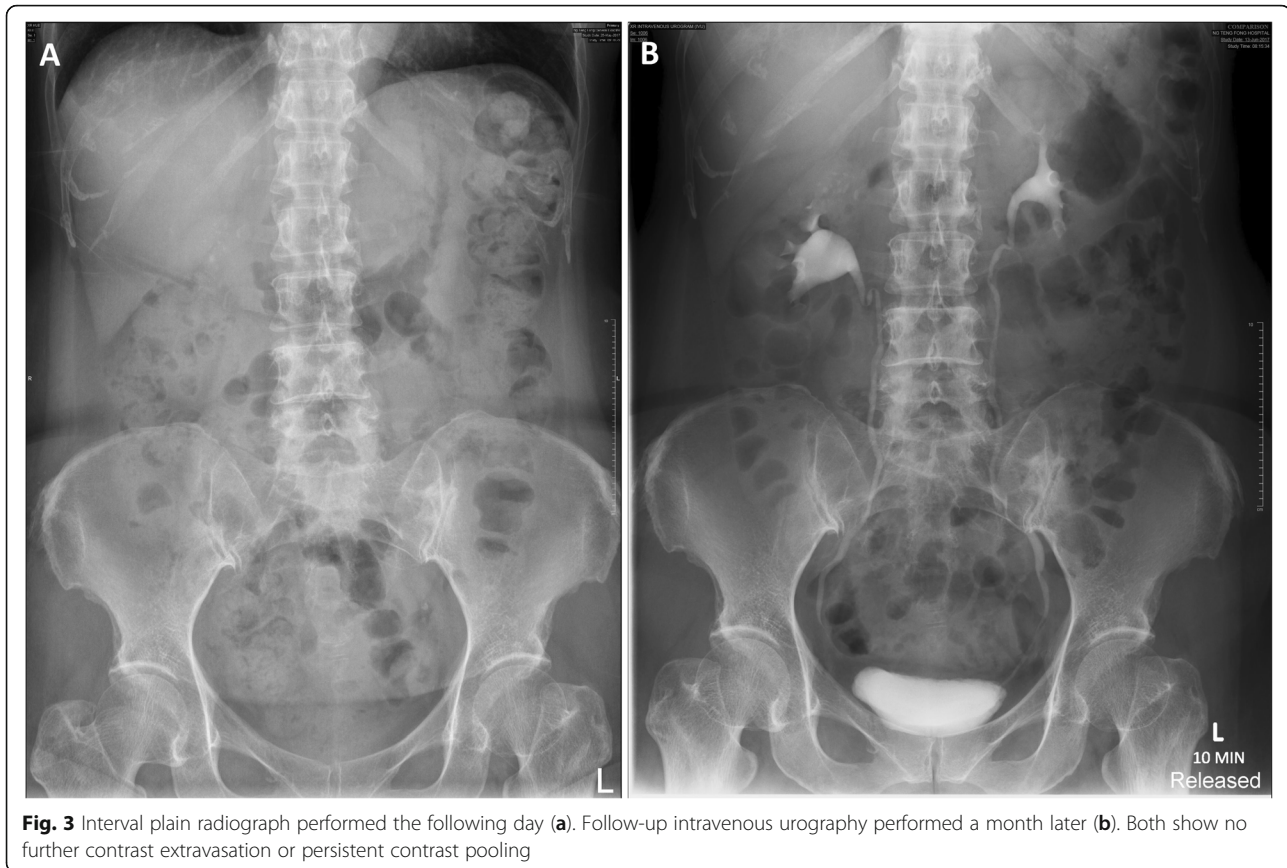
between the administered dose of intravenous contrast and the incidence of peripelvic contrast extravasation in patients with acute renal colic [2].

However, osmotic diuresis alone is an insufficient factor in the absence of obstruction. The primary mechanism is nonetheless likely dependent on this diuretic effect, given the temporal relationship between contrast administration and onset.

Unilateral renal pelvis rupture in the absence of obstruction has been described in the emergency care setting. Patients present first with flank pain, with a following CT demonstrating rupture where no obstruction is identified. Eken et al. suggest that unwitnessed transient obstruction, such as from a passed calculus, may be the most plausible mechanism [6]. Though that reported case had no known history of urinary calculi, another reported by Pampana et al. did [5].

The bilateral nature of rupture in this case makes transient obstruction by a passing ureteric calculus less probable. Moreover, a calculus was only demonstrated on one side prior to contrast administration. Transient obstruction more distally can affect both kidneys and remains a possible mechanism.

One other report of bilateral renal pelvis rupture occurring during contrast-enhanced CT was described by Chien et al. [7]. The case occurred during CT venography of the iliac veins, where a total of 170 mL of



intravenous contrast was administered and post-rupture catheterization drained a urine volume in excess of 1 l. A background of bladder outlet obstruction from prostatomegaly was reported, and the authors attribute it as the cause of rupture. Acute flank pain during the scan first alerted radiological staff of this complication.

Notably, the case we report did not manifest flank pain. There was also no known history or symptom of urinary obstruction, though the bladder did appear distended on CT. It is plausible that voluntary urinary retention acted as a form of transient ‘obstruction’ at the bladder outlet.

Even so, majority of patients with a filled bladder do not develop this complication. The initial presentation of microscopic haematuria in this specific case may hence be relevant. Urinary calculi predispose to urinary tract rupture, with one postulated mechanism of urothelial injury during passage [8]. As no urothelial mass was identified in this case, the cause of haematuria could have been recent asymptomatic passage of calculi. We postulate that this could have additionally predisposed to rupture.

In the case reported by Chien et al., the patient was also treated conservatively. Interval imaging and urinalysis showed resolution of both microscopic haematuria and contrast extravasation. Serial imaging is of value, as large or persistent urinomas carry a risk of infection and

loss of renal function [9]. Other modalities such as sonography can be considered as well [5]. Existing literature suggests that such a conservative approach is appropriate in the absence of complications (e.g. superimposed infection, kidney injury), risk factors for complications (e.g. sizeable urinoma 100 mL or larger) or a solitary kidney [10–12]. The detection of further contrast extravasation or unresolving urinoma in this case would have prompted consideration of drainage and urinary diversion.

In conclusion, spontaneous rupture of the renal pelvis is a potential (albeit rare) complication of intravenous contrast administration in the absence of urinary tract obstruction, and it can occur bilaterally. Although cases can uncommonly be asymptomatic, typical symptoms such as flank pain following contrast injection behoove physicians to evaluate the kidneys – particularly when they are not included in the initial study or no delayed phase is protocolled. A missed or untreated complication (i.e. large urinoma), could become a nidus for intra-abdominal infection and damage the urinary tract by fibrosis and granuloma formation. Rupture should also prompt physicians to actively evaluate for underlying causes. Interval follow-up imaging for resolution is clinically relevant to monitor for and avoid such infective sequelae through radiological-guided drainage or urological intervention.

Abbreviation

CT: Computed tomography

Acknowledgements

Not applicable.

Authors' contributions

LZ wrote the case report and performed literature review. BJCY identified the case, provided its details and reviewed the draft manuscripts. Both authors have read and approved the final manuscript.

Funding

Not applicable.

Availability of data and materials

Not applicable.

Ethics approval and consent to participate

Not applicable.

Consent for publication

Written informed consent for publication of their clinical details and clinical images was obtained from the patient. A copy of the consent form is available for review by the Editor of this journal.

Competing interests

The authors declare that they have no competing interests.

Author details

¹National University Hospital, Singapore, Singapore. ²Ng Teng Fong General Hospital, Singapore, Singapore.

Received: 13 April 2020 Accepted: 6 July 2020

Published online: 13 July 2020

References

- Schwartz A, et al. Spontaneous renal extravasation during intravenous urography. *Am J Roentgenol.* 1966;98(1):27–40. American Roentgen Ray Society. <https://doi.org/10.2214/ajr.98.1.27>.
- Bernardino ME, Clennan BL. High dose urography: incidence and relationship to spontaneous peripelvic extravasation. *Am J Roentgenol.* 1976;127(3):373–6. American Roentgen Ray Society. <https://doi.org/10.2214/ajr.127.3.373>.
- Yanaral, Fatih et al. "Spontaneous rupture of the renal pelvis due to obstruction of pelviureteric junction by renal stone: a case report and review of the literature". *Urol Ann*, vol 9, no. 3, 2017, p. 293. Medknow, doi: https://doi.org/10.4103/ua.ua_24_17.
- Gershman B, et al. Causes of renal fornical rupture. *BJU Int.* 2011;108(11): 1909–11. Wiley. <https://doi.org/10.1111/j.1464-410x.2011.10164.x>.
- Pampana, E. et al. "Spontaneous ureteral rupture diagnosis and treatment". *Case Rep Radiol*, vol 2013, 2013, pp. 1-4. Hindawi Limited, doi:<https://doi.org/10.1155/2013/851859>.
- Eken A, et al. Spontaneous rupture of the ureter. *Singapore Med J.* 2015; 56(02):e29–31. Singapore Medical Journal. <https://doi.org/10.11622/smedj.2015029>.
- Chien JC-W, et al. Bilateral spontaneous peripelvic urinary extravasation. *Kidney Int.* 2014;86(2):448. Elsevier BV. <https://doi.org/10.1038/ki.2013.514>.
- El-Boghdady SA. Spontaneous rupture of the ureter proximal to ureteric stone. *J Royal Soc Med.* 1985;78(3):255–6. SAGE Publications. <https://doi.org/10.1177/014107688507800316>.
- Goldwasser J, et al. Urinoma: prompt diagnosis and treatment can prevent abscess formation, hydronephrosis, and a progressive loss of renal function. *Case Rep Emerg Med.* 2018;2018:1–3. Hindawi Limited. <https://doi.org/10.1155/2018/5456738>.
- Setia SA, et al. Renal fornical rupture in the setting of obstructing ureteral stones: an analysis of stone characterization and urologic intervention pattern. *J Endourol.* 2020;34(3):373–8. Mary Ann Liebert Inc. <https://doi.org/10.1089/end.2019.0706>.
- Sultan MF, et al. Spontaneous fornical rupture: can it be treated conservatively? *Urol Ann.* 2017;9, 41. Medknow(1). <https://doi.org/10.4103/0974-7796.198883>.
- Morgan TN, et al. Renal fornical rupture: is conservative management safe? *Urology.* 2017;109:51–4. Elsevier BV. <https://doi.org/10.1016/j.urology.2017.07.045>.

Publisher's Note

Springer Nature remains neutral with regard to jurisdictional claims in published maps and institutional affiliations.

Ready to submit your research? Choose BMC and benefit from:

- fast, convenient online submission
- thorough peer review by experienced researchers in your field
- rapid publication on acceptance
- support for research data, including large and complex data types
- gold Open Access which fosters wider collaboration and increased citations
- maximum visibility for your research: over 100M website views per year

At BMC, research is always in progress.

Learn more biomedcentral.com/submissions

